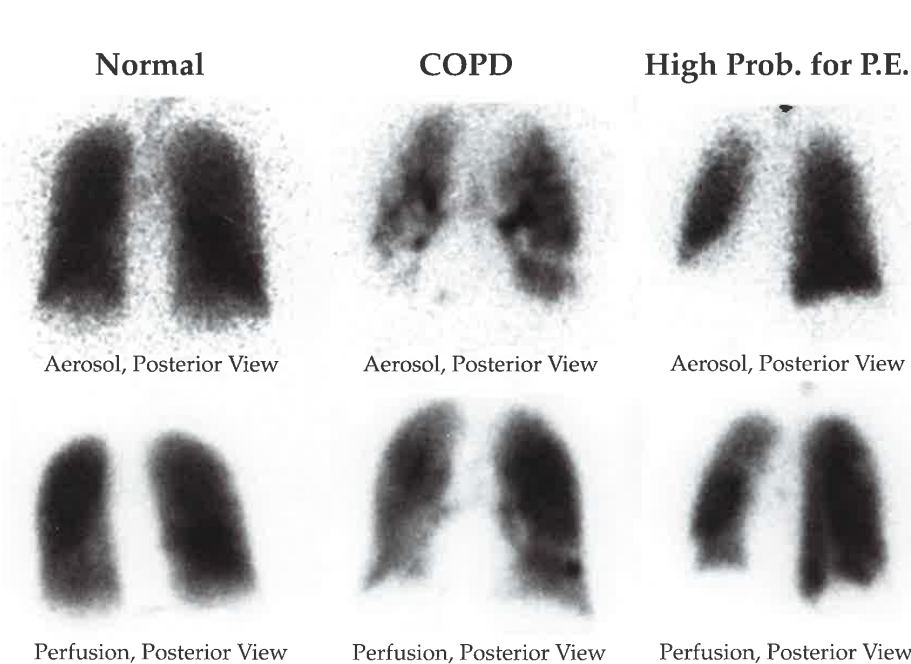


Interpreting V/Q Scans

Why Use V/Q Scanning?

V/Q scans are generally ordered to assess the probability of acute pulmonary embolus (PE). V/Q scans may also be used to check for Chronic Obstructive Pulmonary Disease (COPD), cancer, or other pulmonary disorders in certain instances. V/Q scans can detect changes in gas-exchange potential prior to CT detection of structural changes, which may detect early changes to the lungs to non-invasively diagnose early stages of COPD¹. V/Q scans using Medi/Nuclear® radioaerosol systems may be particularly useful for assessing COPD, due to the very small particles (over 97% of particles under 1 micron and 40.8% less than 0.2µM) generated by the Medi/Nuclear® radioaerosol systems.

Ventilation scans are performed to improve the low specificity of the perfusion scans. V/Q scans are preferable over pulmonary angiography for sensitive patients, such as children, pregnant women, and those with clear lungs on x-ray, due to the lower dose of radiation. Patients with contrast allergy and nephrotoxicity, as well as claustrophobia and obesity, also warrant the use of V/Q scanning for PE over CT angiography.²



Interpretation Criteria for PE

The criteria for categorizing V/Q scans is according to the likelihood that PE will be demonstrated on CT angiography. Several sets of criteria exist to determine the sensitivity and specificity of V/Q scans in identifying the presence (or absence) of PE (e.g., PLOPED, modified PLOPED II).

Interpretation of scans is based on determining whether the perfusion scan defects correspond to the anatomic segments or sub-segments of the lung. The size and number of segmental defects are used to estimate the likelihood that the defects are due to PE.

An evaluation of the likelihood of PE according to the clinical presentation is of great importance in the interpretation of diagnostic test results and selection of an appropriate diagnostic strategy.³

*Note the peripheral penetration on all aerosol images, especially COPD.
Images courtesy of Alan Waxman, M.D., Cedars-Sinai Medical Center, Los Angeles*

Terms

Ventilation/perfusion (V/Q) ratio: The ratio of the amount of air reaching the alveoli (“V” ventilation) to the amount of blood reaching the alveoli (“Q” perfusion).

V/Q match: A perfusion defect that has any ventilatory abnormality of comparable size.

V/Q mismatch: A perfusion defect that has no corresponding ventilatory abnormality, or a defect that is more severe or larger than the ventilatory abnormality.

Triple match: Perfusion defects that match ventilation and abnormalities shown in chest X-ray (CXR) in size and location.

Solitary triple match: A matched V/Q defect with associated matching CXR opacity.

Stripe sign: A thin line (stripe) of perfused lung tissue at the pleural surface of a perfusion defect. A stripe sign may be best seen on a tangential view.

Interpretation Criteria^{a, 4, 5}

PE Present (high probability)

- Two or more mismatched (V:Q) segmental defects

^a Modified PLOPED II criteria.

PE Absent (normal perfusion or very low probability)

- Nonsegmental perfusion abnormalities; these were enlargement of the heart or hilum, elevated hemidiaphragm, costophrenic angle effusion, and linear atelectasis with no other perfusion defect in either lung
- Perfusion defect smaller than corresponding radiographic lesion
- Two or more matched V/Q defects with regionally normal CXR and some areas of normal perfusion elsewhere in the lungs
- One to three small segmental defects (<25% of segment)
- Solitary triple-matched defect in the mid to upper lung zone confined to single segment
- Stripe sign
- Pleural effusion of one-third or more of the pleural cavity with no other perfusion defect in either lung

Nondiagnostic (low or intermediate probability)

- All of other findings

Identifying Non-PE Diseases and Abnormalities

A comparison of ventilation to perfusion with corresponding CXR may indicate COPD or other non-PE abnormalities. Nonsegmental defects that do not correspond to segmental anatomy are less likely to be due to PE;⁶ however, it is sometimes difficult to determine whether a defect is segmental or nonsegmental.⁷

Non-wedge perfusion defects may be seen in patients with COPD, pneumonia, lung cancer, alveolar edema, or interstitial lung disease.⁸ COPD may be the most common disease associated with non-wedge perfusion defects and has a variety of perfusion defect patterns, such as “irregularly decreased tracer activity diffusely to the presence of large and usually symmetrical non-wedge perfusion defects (indicating significant emphysema).”⁸ However, a perfusion defect pattern associated with COPD does not by itself rule out concurrent acute PE disease. There are no proven clinical criteria to help differentiate acute PE from COPD, due to the overlap and non-specificity of the clinical features common to both diseases.⁹

Pneumonia is also associated with various non-wedge perfusion defect patterns, from “an unilateral focal non-wedge defect or diffuse and irregularly decreased perfusion activity corresponding to chest X-ray findings.”⁸ A lung tumor will appear as a non-wedge perfusion defect and can easily be correlated to its location on chest X-ray or CT exam.⁸

References

- ¹ Jobse, Brian N., et al. “Detection of Lung Dysfunction Using Ventilation and Perfusion SPECT in a Mouse Model of Chronic Cigarette Smoke Exposure”. *Journal of Nuclear Medicine* 2013: 54 616-623.
- ² Freeman, Leonard M. “Don’t Bury the V/Q Scan: Its’ as Good as Multidetector CT Angiograms with a Lot Less Radiation Exposure.” *Journal of Nuclear Medicine* 2008: 49(1): 5-8.
- ³ Torbicki, Adam, et al. “Guidelines on the Diagnosis and Management of Acute Pulmonary Embolism”. *European Heart Journal* 2008: 29(18): 2276-2315.
- ⁴ Parker, J. Anthony, et al. “SNM Practice Guideline for Lung Scintigraphy 4.0”. *Journal of Nuclear Medicine Technology* 2012: 40(1) 57-65.
- ⁵ Sostman, Dirk H., et al. “Acute Pulmonary Embolism: Sensitivity and Specificity of Ventilation-Perfusion Scintigraphy in PIOPED II Study”. *Radiology* 2008: 246(3) 941-946.
- ⁶ *Fundamentals of Diagnostic Radiology*. 4th Edition. Brant, William and Helms, Clyde, eds. Lippincott Williams and Wilkins. 2012.
- ⁷ *Nuclear Medicine in Clinical Diagnosis and Treatment*, 3rd ed. Ell, Peter J. and Gambhir, Sanjid Sam, eds. Churchill Livingstone. 2004.
- ⁸ *Nucmedresource.com*. Online. 10 September 2013. <http://www.nucmedresource.com/pulmonary-nm-vq.html>.
- ⁹ Moua, Teng and Wood, Kenneth. “COPD and PE: A Clinical Dilemma”. *International Journal of COPD* 2008: 3(2) 277-284.

Additional Resources

Williams, Scott. “Pulmonary Embolism”. *Aunt Minnie.com*. 3 April 2002. Online. 11 September 2013. <http://www.auntminnie.com/index.aspx?sec=ser&sub=def&pag=dis&ItemID=54625>.